

Review – MISTURITION DYSFUNCTION

Update on pudendal nerve entrapment syndrome: an anatomical and surgical approach, diagnosis and therapy.

F. Itza Santos(a), J. Salinas(b), D. Zarza(c), F. Gómez Sancha(d) y A. Allona Almagro(e)

a)Pain Unit, Pain Clinic, Madrid, España

b)Urology Department, Hospital Clínico San Carlos, Madrid, España

c)Neurophysiology Department, Hospital NISA Pardo de Aravaca, A Coruña, España

d)Urology Department, Clínica del Rosario, Madrid, España

e) Urology Department, Rúber Internacional, Madrid, España

Palabras clave:

Nervio pudendo (NP).

Atrapamiento del nervio pudendo (SANP).

Dolor neuropático del suelo pélvico.

Síndrome miofascial de suelo pélvico. Descompresión del nervio pudendo.

RESUMEN

Introducción: El síndrome de atrapamiento del nervio pudendo (SANP) es un gran desconocido y suele ser mal diagnosticado o confundido con otras patologías. Fue descrito por primera vez por Amarenco en 1987. La manifestación clínica clásica es la neuralgia del pudendo, un dolor neuropático del área genital.

Objetivos: Dar a conocer su existencia a los profesionales de la urología a través de una revisión sistemática de la bibliografía existente y sus posibilidades de diagnóstico y tratamiento.

Material y método: Realizamos una búsqueda bibliográfica a través de la base de datos «Pubmed» utilizando los términos «Pudendal nerve», «Pudendal nerve entrapment síndrome», «Pelvic floor neuropathic pain», «Pelvic floor myofascial síndrome», «Pudendal nerve decompression». Asimismo, seleccionamos los trabajos en lengua inglesa, española y francesa, revisando también los artículos que dichos trabajos refieren.

Resultados: Se desarrollan los aspectos más destacados del síndrome: anatomía, etiología, fisiopatología, diagnóstico clínico, ecodoppler de la arteria pudenda interna, estudios electrofisiológicos, criterios diagnósticos, terapéutica médica, tratamiento con fisioterapia y tratamiento quirúrgico.

Conclusión: Es una causa poco frecuente de dolor en el suelo pélvico y afecta en gran medida la calidad de vida de los pacientes. Hoy, disponemos de herramientas diagnósticas y terapéuticas que nos permiten tratar este síndrome invalidante con buenos resultados.

Key words:

Pudendal nerve.
Pudendal nerve entrapment syndrome.
Pelvic floor neuropathic pain.
Pelvic floor myofascial syndrome.
Pudendal nerve decompression.

Update on pudendal nerve entrapment syndrome: an approach anatomic- surgical, diagnostic and therapeutic

ABSTRACT

Introduction: The syndrome of pudendal nerve entrapment (SANP) is widely unknown and often misdiagnosed or confused with other diseases. It was first described by Amarenco in 1987. The classic clinical manifestation is pudendal neuralgia, a neuropathic pain in the genital area.

Objectives: To make known its existence to the urology professionals through a systematic review of existing literature and its potential for diagnosis and treatment.

Materials and methods: We performed a literature search through the database "Pubmed" using the terms "Pudendal nerve", "Pudendal nerve entrapment syndrome", "Pelvic floor neuropathic pain", "Pelvic floor myofascial syndrome," "Pudendal nerve decompression". Also, selected works in English, Spanish and French, also reviewing the articles relate this work.

Results: We develop the highlights of the syndrome: anatomy, etiology, pathophysiology, clinical diagnosis, ecdoppler of internal pudendal artery, electrophysiological studies, diagnostic criteria, medical therapy, physical therapy treatments and surgery.

Conclusion: It is an uncommon cause of pain in the pelvic floor and greatly affects quality of life of patients. Today, we have diagnostic and therapeutic tools that allow us to treat this disabling syndrome with good results.

Introduction

Pudendal nerve entrapment syndrome was described by Dr. Amarenco in 1987. He came across this syndrome when a cyclist visited him complaining about pain in the pudendal area. He would run some electrophysiological tests to determine the anomaly. At first, he called it perineal paralysis of cyclists (1). Soon after, in 1991, Dr. Shafik would describe the technique for pudendal nerve decompression. The procedure is simple and ambulatory. It lasts 5-10 minutes in expert hands, with no complications except for infections, small hematomas and postoperative pain (2). The main reason for patients to consult the doctor is pain in the anal and perineal area. This pain particularly appears when sitting down, relieves when getting up and disappears when lying in bed. Among its neuropathy symptoms we can find hypoesthesia, numbness, perineal tingling and even severe electrical shocks (3). In a retrospective study, Benson shows that we are dealing with an entity few practitioners think of. This will lead to a significant pilgrimage of patients before being correctly diagnosed. Moreover, we can find cases in which neurophysiologic findings showed values within normal limits, increasing the difficulty of the problem (4). Similarity between PNE symptoms and myofascial pain syndrome of the pelvic floor will be constant. Sometimes they will co-exist and sometimes one of these entities will lead to the other; distinctive pains of both syndromes are overlapped or some of them stand out on the others, making their diagnosis and later treatment more difficult (5). As for epidemiological records, there are not too many in the existing literature. The average time of diagnosis is 4 years, ranging from 1 to 15 years. Doctors visited before diagnosis range from 10 to 30. Sex of course is important, being more females affected. Seven out of ten are women. The actual impact of this condition is still unknown.

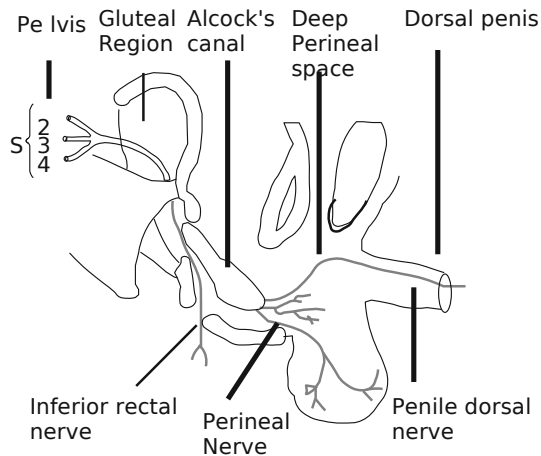
Objectives: to make known its existence to the urology professionals through a systematic review of existing literature and its potential for diagnosis and treatment.

Materials and methods: We performed a literature search through the database "Pubmed" using the terms such as "Pudendal nerve", "Pudendal nerve entrapment syndrome", "Pelvic floor neuropathic pain", "Pelvic floor myofascial syndrome," "Pudendal nerve decompression". We also selected works in English, Spanish and French, reviewing articles related to this topic too. Finally, we chose between those works that better fit the PNE profile, ruling out second ones and successive manuscripts by the same author or authors that did not add up any relevance to the treated subject.

Results: we developed the highlights of the syndrome: anatomy, etiology, pathophysiology, clinical diagnosis, Doppler ultrasound in internal pudendal artery, electro-physiological studies, diagnostic criteria, medical therapy, physical therapy treatments and surgery.

Brief anatomic-surgical summary

The pudendal nerve (PN) (picture 1) as it follows its path, goes through some intricate passages; this is the reason why nerve entrapment easily occurs (6).



Picture 1. Pudendal Nerve pathway.

PN anatomy has profusely been described by significant anatomists, but the electro-physiological records show that the origins of the different branches differ with those mentioned by the conventional anatomy which agrees with Bisschop et al's anatomic and neurophysiologic investigations (7).

Shafik tells us about surgical anatomy and its implications, in a revealing article, after having examined 26 corpses; following transperineal and transgluteal paths that we will see in the surgical treatment area later on (8).

Robert et al, through anatomic investigation on corpses, believe that critical points to find entrapments at PN would be: the point between the sacrotuberous and sacrospinous ligaments, Alcock's canal and the falciform process (9).

We find ourselves before a complex anatomy, however necessary to explain the pathology caused by the entrapment. PN has its origin at the sacral spinal segments: S2, S3 y S4.

The anatomy of nerve endings is very complex and has many variants. However, we will be able to relate the pain to its possible pudendal origin if we know the sensory areas innervated by the pudendal nerve.

PN has got 3 terminal branches: inferior rectal nerve, perineal nerve and dorsal nerve of penis and clitoris. PN innervates the bulbospongiosus and ischiocavernosus muscles, external anal sphincter, levator ani and superficial and deep perineal nerve. Variability in the innervation of the levator ani muscle expressed by Grigorescu after studying 17 corpses should put us on the alert for its clinical and surgical repercussions (10).

The 3 terminal branches have a different proportion of motor, sensory and autonomic fibers. Therefore, their entrapment can cause signs or symptoms in any of its 3 areas. In total, it is estimated that 30% will be autonomic and 70% will be somatic (50% sensory and 20% motor).

Pudendal nerve innervations will be (6), (11):

- **Sensitive:** perineal skin and genitals.
- **Motor:** external anal sphincter, levator ani muscle, bulbospongiosus and ischiocavernosus muscles, urethral striated sphincter and superficial and deep perineal nerve.
- **Vegetative:** erection and sense of urgency to urinate.

Etiology and events that lead to injury

Bautrant et al analyzed the possible causes that might lead to PNE. They found out that childbirth, direct falls on the tail-bone, cycling and pelvic surgery are frequent triggers for this nosologic condition (12).

Cycling is the common reason mentioned by Amarenco in order to suffer from nerve entrapment and we figure out that similar sports might produce the same results(1); temporary erectile dysfunction is a frequent companion to amateur cyclists (13). Chronic constipation and perineal descent are given as one of the first causes to trigger off PNE (14). In a very interesting article Shafik mentions the importance of rectal prolapse and rectal incontinence to cause PNE. He finds abnormal electromyographic and electroneurographic values, along with perineal hypoesthesia. He treats it with decompression and obtains encouraging results (15). Vulvar pain associated with chronic constipation and incontinence may be connected to PN entrapment as Shafik showed in his study of idiopathic vulvodynia. 9 out of 11 patients experienced no pain after decompression (16). Surgery involving vaginal dissection may produce compressive neuropathy of the PN as Benson will tell (17). The practice of sport during adolescence may lead to an inadequate development of the spinous process of the ischium that will end up in an ulterior compressive neuropathy over the years (18). After all this, it will be easy to understand that repetitive micro-trauma injuries to the perineal area can lead us to PNE (19). Only by passing through a muscle anywhere on the body, a nerve of that segment may be trapped and cause an injury or nerve dysfunction (20). Lien et al describe nerve stretch during childbirth as a possible etiology (21). The episiotomy can be the source of some cases of neuropathy of the PN, therefore we will be very vigilant when carrying it out, as evidenced by a report of Soga et al based on the observation of 15 elderly female corpses (22).

Pathophysiology of nerve entrapment

Three main factors can be identified in the development and pathology of the nervous system: vascular, ionic and mechanical. There is no agreement about which one of them is predominant, particularly in the early stages of the compression. Today it is thought that vascular factors predominate over the others (23). Nerve fibers depend on a continuous blood supply for their normal functioning.

There is a group of pressure gradients in the nerve and tissues, and fluids surrounding the nerve too. The importance of this pressure gradient in the development of entrapment is a fact(24). Sunderland detailed 3 progressive stages by increased pressure in the trapped area: hypoxia, edema and fibrosis (23). Venous stasis and hypoxia weaken the metabolism of the nerve. Neuroischemia is a source of pain and other symptoms such as paresthesia. With continuous hypoxia, the injury to the capillary endothelium causes extravasation and edema rich in proteins. Ischemia in the nerve is going to translate into a blockade of the nerve transmission. Three may be the causes:

- Excessive strain,
- Minimum strains on areas where there are adhesions.
- Mechanical compression.

The development of these changes will be as follow:

- Obstruction of venous return that causes congestion or venous stasis.
- Anoxic injury that increases permeability.
- Edema in the endoneurial tissue, with increased pressure on the intrafascicular space, which increases the effect of the original compression.

Whether the compression is increased or the edema persists for a long time, fibroblast proliferation within the nerve takes place and a demyelinating process previously occurs. If the cause persists, fibrosis may develop and cause anoxic nerve segments, since circulation and nutrient exchange between the vascular plexus and nerve fibers are blocked. When a portion of the axon undergoes ischemia, with a small reduction in blood flow of 30-50%, the reduction of the oxidative phosphorylation and ATP production decrease the effectiveness of the Na pump, the axonal transport system and cell membrane integrity, and consequently there is a decrease or loss in the transmission along nerve fiber. Nutrients are supplied by 2 anterograde axoplasmic transport mechanisms and catabolic are collected by a retrograde axoplasmic transport mechanism. The interruption of the synthesis or alterations in transport in both directions seems to be the reason for the phenomenon of double or multiple-compression («double-crush») which means that a nerve with a conduction disorder at one level is more vulnerable to a conduction disorder at a second or a third location. Initially, it was observed that neural pathologies at proximal level predisposed to the development of distal alterations. It is now clear that primary distal alterations favor the emergence of proximal disorders too (24).

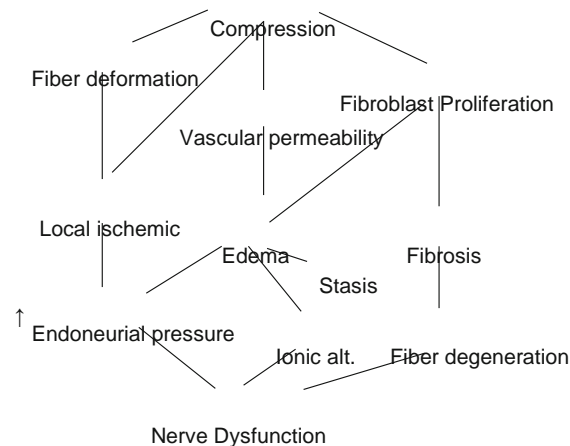


Diagram-Pathophysiology of nerve entrapment.

Clinical diagnosis of entrapment

History

- Pelvic pain with sitting that may be less intense in the morning and increase throughout the day. Symptoms may decrease standing or lying down. The pain may be perineal, rectal or in the penile/clitoral area. It may be unilateral or bilateral too.
- Sexual dysfunction. In women and men, it manifests as pain or decreased sensation in the genitals, perineum or rectum (Hypoesthesia). The pain may occur with or without touch. I may cause anorgasmia. In men, dysfunction presents as pain during erection, difficulty sustaining an erection or painful ejaculation.
- Difficulty with urination/defecation. Patients may experience urinary frequency or urgency. Post-void discomfort. They may have painful bowel movements and feel pain after defecation. Constipation is common. They may have the feeling of having a golf ball in the rectal area. We can also find frequently complete or partial urinary and fecal incontinence.
- On the other hand, it can simulate chronic prostatitis, prostatodynia or interstitial cystitis.
- Today we know that the most common cause of prostatodynia is pelvic floor dysfunction associated with myofascial pain. We will be faced as Shafik pointed out, with a pattern of persistent perineal pain with frequency, urgency, dysuria and changes in urine flow. In his article he proposes pudendal nerve decompression (25).

Pain patterns

To simplify and from a clinical and practical point of view we can see the following pain patterns:

- Only pain.
- Pain with urinary symptoms.
- Pain with defecation problems.
- Pain with erectile and ejaculatory-dysfunction.
- Any of the above together.
- Dysfunctions without pain.

Shafik reports 2 groups of patients without pain but with erectile dysfunction and hypesthesia or anesthesia of the penis, perineum and scrotum. Pudendal nerve and bulbocavernosus latencies were found increased (PNTML). PN decompression was effective for the treatment of DE and the accompanying symptoms. It is also suggested that the most likely cause for this would be chronic constipation which would lead to subluxation of the levator ani and then to a compression of the PN in the Alcock's canal (26).

Loeser, a pain expert, says that entrapment neuropathies cause focal neurological deficits, local and radiating pain and paresthesia. These three components may or may not occur. For this reason, we find a lack of correlation between clinical and electrophysiological findings (27).

Physical examination

- Normally we will find sore muscles, muscle strain, shortened muscles, triggers points, taut bands and increased tone.
- It may become sensitive to touch at the exit of Alcock's canal. Beco et al use a scale to determine whether the pain is significant or not when we touch the exit channel; it will be significant if they find moderate-severe pain with Tinel's sign (reproduction of pain and paresthesia by pressure on the nerve trunk) (28).
- The skin rolling test is often positive; it consists in pinching a roll of skin and pulling it from the anus to the pubis, on the pathway of the pudendal nerve branches, searching for a sharp pain in the innervated area.
- We will find a sensory decrease at the perineal and anal area (28).

Doppler ultrasound in pelvipерineal vessels

This form of diagnose is quite new, noninvasive, easy to perform and causes little discomfort to the patient. Mollo et al published a very interesting study where they compare Doppler ultrasound effectiveness via endocavitary with traditional electroneurographic and electromyography assessments, diagnostic criteria and surgical results (29).

Electro-physiological studies

Those who want to understand in a clearer way the neurophysiology of the pelvic floor can read a Spanish study written by Dr Hernández-Hidalgo (32). Apart from that, we have to understand that the neurophysiological study of the pudendal nerve covers nerve structures such as motor, sensory and vegetative. This will involve techniques that try to objectify the status of this pathway from a functional point of view, reporting the extent and severity of neuropathic damage and applying specific tests for each aspect that we wish to examine (30):

• Motor nerve conduction study (distal motor latency of pudendal nerve).

This test will measure the time from stimulation of the pudendal nerve at the ischial spine to the response of the external anal sphincter. This test does not indicate the extent of injury. To measure the pudendal nerve motor latency a special device was developed at St. Mark's London Hospital (Dr Kiff and Dr Swash) (31). It consists of a bipolar stimulating electrode fixed on a gloved index finger and two surface electrodes for recording mounted 3 cm. proximally at the base of the finger. The stimulating electrode is inserted into the rectum and placed on the ischial spine. The recording electrode is placed on the external anal sphincter. With this method the normal latency is 2.0 msec (picture2).

• Somatic sensory pathway study.

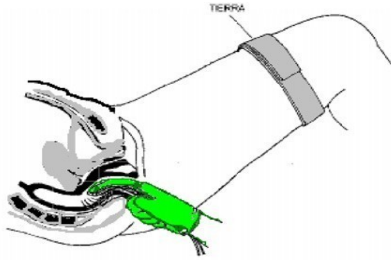

- **Sensory thresholds:** we determine the threshold of perception and pain by increasing electrical stimulation on the dorsal nerve of penis/clitoris. Comparing the values of stimulation of the patient with normal subjects, we can determine if they are altered.

• Sensory evoked potentials of the pudendal nerve:

it evaluates the peripheral and spinal sensory pathway. It measures the time that an electrical stimulus takes to travel the peripheral nerve, posterior roots of the spinal cord, until we collect the brain's response at parietal level. This time is about 40msec in normal subjects (picture 3).

• Autonomic pathways study (sympathetic skin response).

- the assessment of efferent pathways is performed by stimulating skin reflexes and comparing the response at hands and genitals. Sympathetic skin response (SSR) measures sweat glands activity as a transient change in the electrical potential of skin (picture 4).



Picture 2. St. Mark's electrode and rectal use

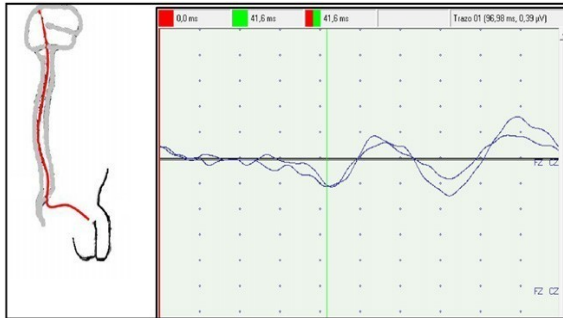
• Electromyography of muscles related to the pudendal nerve (bulbocavernosus, external anal sphincter...).

This technique allows us by analyzing the muscle activity at rest or during voluntary activity to determine if there is denervation on the muscle structure, establishing whether this event is active or has become chronic. By studying different muscle groups, we can determine the topography of the lesion and then clarify the diagnosis.

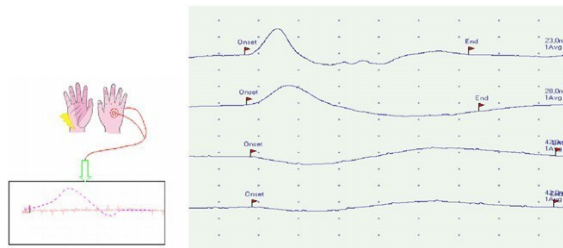
• Sacral reflex

Using this technique we measure the time that it takes to trigger a muscle contraction in the bulbocavernosus muscle after electrical stimulation of the dorsal nerve of penis or clitoris. With this technique we evaluate motor and sensory fibers of the pudendal nerve and roots and spinal segments located between S2 and S4. In normal subjects this reflects arc takes between 30 and 40 min (picture 5).

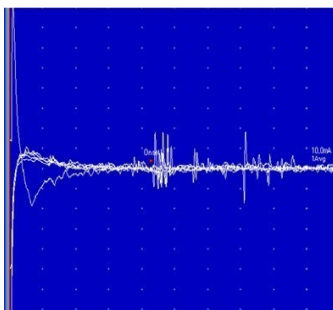
Bisschop describes other sacral reflexes that will help us identify the exact site of the entrapment (30).



Picture 3. Sensory evoked potentials of the pudendal nerve.



Picture 4. Sympathetic skin response.



Picture 5. Sacral reflex.

Diagnostic Criteria

The description and determination of diagnostic criteria for a specific disease entity allow the clinician a better approach and address to the problem. Classically, this system has been used for better understanding, teaching, diagnosis and possible treatment of complex syndromes. PNS is no exception and here we are going to show those criteria (11). However these criteria should be validated and agreed upon in ad hoc international conference.

1. major criterion +2 minor criteria.
2. major criteria.

• Major criteria

1. Painful area at the end of pudendal nerve.
2. Reproduction of pain by pressing the pudendal nerve trunk (equivalent of Tinel's sign).
3. Improvement of the pain for at least 12h after injection of lidocaine in specific anatomical sites of the pudendal nerve pathway.

• Minor criteria

1. Neuropathic pain.
2. Existence of a painful and/or antalgic position (worse sitting, better lying down).
3. Existence of an etiological factor: trauma, surgery, childbirth, falls, sports etc.
4. No other cause of pain in the pelvic area
 - o Endometriosis.
 - o Uterine myoma.
 - o Uterine fibroma.

Treatment

Logically, as with any pathological condition, the treatment has to be sequential and begin with the less aggressive measures.

Medical treatment

• Symptomatic treatment of pain.

Several classes of drugs have been used with varying effectiveness to treat neuropathic pain. Antidepressants are mostly used, amitriptyline and anticonvulsants such as gabapentin or pregabalin are also included. Topical local anaesthetics such as lidocaine 5% gel are recommended too (33). Amitriptyline is often the drug of first choice since it became the most used and has the best results. It has been considered for a long time the first choice in the treatment of neuropathic pain. Pain relief seems to be due to the inhibition of norepinephrine and serotonin re-uptake in the presynaptic terminals, thus activating the endogenous pain inhibitory systems in the brain which modulate pain transmission at the spinal cord cells.

Benzodiazepines are used in the treatment of myofascial pain and PNS. Clonazepam has the best results.

It starts with 0,25mg/day, increasing 0,25mg/week, up to a maximum of 5-20mg/day. The treatment should not be considered ineffective before 4 weeks. In a 60 day study of clonazepam for temporomandibular joint dysfunction, analysis at 30 days showed significantly lower pain intensity scores with the anticonvulsant compared with placebo (Harkins, 1991)³⁴. Anyway, the response to this type of conservative treatment is a mild or moderate improvement. In a recent publication, we found that gabapentin, either alone or in combination with amitriptyline, may produce a significant improvement in this type of pain (35).

• Corticosteroid injection treatment.

Perineural injections with corticosteroids and lidocaine/bupivacaine, into interligamentary space and into Alcock's canal, under fluoroscopy or CT scan (36), lead to a noticeable improvement in the symptoms in many cases. They relax hyper-tonic sphincters, suppress bladder symptoms and normalize sexual dysfunction too. Its duration of action goes from hours to weeks and in some patients up to recovery. Symptomatic relief depends on the accuracy of injection technique due to a highly variable anatomy. The improvement in sensory, motor or autonomic symptoms is variable. They are administered every 4-6 weeks and up to a maximum of 3 injections. If there is no adequate response, the possibility of surgical decompression will be assessed (32).

• Physiotherapy.

A long lasting contracture with the corresponding

muscle shortening leads to a neurovascular bundle injury. The degree of injury and nerve entrapment will depend on several factors already mentioned. If performed by physiotherapists who have specialized training in pelvic condition, muscle stretching can get amazing results. Not only will the improvement focus on the pain but it will also relieve patients from other symptoms such as urinary frequency, erectile dysfunction, libido, feeling of golf ball in rectum, etc (37).

• Dry needling or local injections of lidocaine.

In order to deactivate trigger points of muscles affected in the pelvic floor, when dealing with a peripheral nervous system dysfunction, we can use these techniques that will help release the trigger points and decrease the symptoms. These actions are aimed to desensitize the central and peripheral nervous system (38).

Surgical Treatment

It aims to achieve pudendal nerve decompression. Among the findings in surgical treatment we should mention (39):

- Hyper-trophic ligaments, often with sharp edges and protrusions.
 - Fused ligaments (funicular). Ligamentous bands that pass through the nerve.
 - Adhesions, adherence and compression against the sacrotuberous ligament.
 - Proximal branching: inferior rectal branch penetrating the sacrospinous ligament.
 - The main nerve trunk passes through the coccygeus muscle. Elongated ischial spine. NP entrapment usually occurs (32):
 - Between the sacrospinous ligament and the sacrotuberous ligament (ligament clamp, 70% of cases).
 - In Alcock's canal, 20%.
 - Both cases simultaneously, 20%.
 - In the urogenital diaphragm (dorsal nerve).
- We may find three different surgical approaches ([table 1](#)): transperineal, transgluteal and trans-ischioanal.

• Transgluteal approach.

Described by Robert, this technique is bloodier than the previous one and requires hospitalization. A gluteal incision of about 10cm is made. Its main objective is the claw caused to the PN by the sacrospinous and sacrotuberous ligaments. After having treated 400 patients surgically, Robert assures that there was no major complication. A 4 year follow-up will obtain significant improvements, although he admits that subsequent rehabilitation treatment, such as physiotherapy, may be necessary.

It requires 2 days of hospitalization. It may take between 10 days to 3 months of recovery before returning to work. Complete recovery can happen, but complications may occur such as urinary retention in 5% of patients, requiring further probing. Neuropraxia may take several weeks before complete resolution of symptoms (41).

Table 1 Surgical Approach			
Techniques	Transperineal	Transgluteal	Transvaginal-ischiorectal(males)
Incision size	small	large (10cm)	small
Visual control of nerve	-	++	-
Alcock's canal access	+++	+	+
Sacrospinous ligament access	++	+++	+++
Clamp opening between ligaments	without	with	with (partially)
Gluteal muscle incision	No	Yes	No
Effect on urinary and anal incontinence	Yes	??	??
Disadvantages	Blind procedure- Difficult to learn and teach	Side effects- section ligaments	Side effects- section ligaments

evacuation and drainage

• **Transvaginal or Trans-ischiorectal approach.**

Described by Baurant, this technique is performed vaginally in women, hence the name, and anally in men (trans-ischiorectal technique) (32).

The 3 segments of the PN are reached through the ischiorectal fossa. We also access this avascular space through the vagina with the patient in the lithotomy position. The dissection of the ischiorectal fossa will allow exposing the medial face of each side of the pelvis after having rejected the rectum and levator ani. The purpose of this operation is to decompress the locations involved in the canal syndrome; therefore there is no neurolysis or dissection near the nerve.

During the postoperative care 38% of cases experience intense pain in the gluteal area, being this pain different from the one previously reported. This may be attributed to the section of the sacrospinous ligament and the large amount of nervous tissue on some of them. The pain will gradually decrease and end up disappearing completely.

Decompression always starts by opening the canal under the piriformis muscle at the inferior side of the sacrospinous ligament.

Once the perineural fat is reached we proceed to explore the compression area. The dissection of the sacrospinous ligament was performed to release the "clamp", in 90% of cases.

If necessary, the operation may continue caudally, cutting the fibers of the falciform process of the sacrotuberous ligament to penetrate into Alcock's canal. At this stage, we will perform a digital examination of the canal to complete the decompression and make sure the entire canal has been released.

Hematoma formation can usually be prevented by draining the ischiorectal cavity for 48 hours. Hospitalization may last 3-4 days. Then analgesic physiotherapy and perineal re-education is recommended.

Nerve regeneration may take 6-8 months. The complications described in decompression surgery are low:

- Infections: ITU (7%), abscesses (2,5%) with

- Hemorrhagic Complications: 2%, injury to pudendal artery branch and false secondary aneurysm in branch of the superior gluteal artery. The alleged instability and overloading of the sacroiliac joint, as a side effect to the section of the ligaments, has not yet been demonstrated in the existing literature (32).

Publications

The first publications on surgical decompression include small group of patients. As the diagnose has been recognized, the number of patients that underwent surgical decompression has gradually increased and authors such as Robert has reported 400 surgeries since 1989 (41). Baurant reported 104 decompressions (32), Beco 74 (28), Mouchel 192 (42) and Popeney 58 (39). We can see that the majority of the interventions have been performed on this side of the Atlantic, except for the ones performed by Popeney's team.

Persistence of pain after decompression

Persistence of pain may have a number of causes, Weiss mentions (43):

- Myofascial trigger points in the pelvic floor that may even have preceded surgery. They can be further aggravated by surgical trauma.
- Subcutaneous tissue sensitivity which is an important perpetuator of post-surgical pain.
- Sacroiliac joint dysfunction caused by transecting the sacrospinous and sacrotuberous ligaments. A myofascial dysfunction may occur and generate trigger points.
- Pudendal nerve branch pathology. It is the most frequent cause of pain and also the most persistent to treatment.
- There are other factors such as stress, insomnia, hormones and diet
- Central sensitization.

Conclusion

From this review we deduce that pudendal nerve entrapments are more frequently diagnosed than we thought, but the actual frequency is unknown.

The professionals involved (urologist, gynecologist, proctologist, neurologist, algologist...) should make an effort to divulge the existence of this syndrome so disabling and so little known.

We should not overlook the important relationship between PNS and myofascial pain syndrome, since many times we will not know which one brought the other.

The results of both conservative and surgical treatments are more than acceptable, but we will always keep in mind that we have to begin with the less invasive.

Conflict of interest

The authors declare that they have no conflict of interest.

Bibliography

1. Amarenco G., Lanoe Y., Perrigot M., Goudal H. A new canal syndrome: compression of the pudendal nerve in alcock's canal or perineal paralysis of cyclists. *Presse Med.* 1987; 16:399.
2. Shafik A. Pudendal canal syndrome: description of a new syndrome and its treatment. Report of seven cases. *Coloproctology.* 1991; 13:102-9.
3. Robert, et al. Neuropathic pain: a tunnel syndrome. *Surg-Radiol Anat.* 1998; 20:93.
4. Benson J.T., Griffis K. Pudendal neuralgia, a severe pain syndrome. *Am J Obstet Gynecol.* 2005; 192:1663-8.
5. Prendergast S.A., Weiss J.M. Physical therapy and pudendal nerve entrapment. *Advance.* 2004; 15:47.
6. Rouviere. *Anatomia Humana.* vol. 2, tronco. Editorial Masson; 2005.
7. Spinosa J.P., De bisschop E., Laurencon J., Kuhn G., Dubuisson J.B., Riederer B.M. Sacral staged reflexes to localize the pudendal compression: an anatomical validation of the concept. *Rev Med Suisse.* 2006; 2: 2416-8-2420-1.
8. Shafik A., Doss S.H. Pudendal canal: surgical anatomy and clinical implications. *Amer Surg.* 1999; 65:176-80.
9. Robert R., Brunet C., Faure A., Lehur P.A., Labat J.J., Bensignor M., et al. Surgery of pudendal nerve in various types of perineal pain: course and results. *Chirurgie.* 1993-94; 119:535-9.
10. Grigorescu BA, Lazarou G, Olson TR, Downie SA, Powers K, Greston WM, et al. Innervation of the levator ani muscles: description of the nerve branches to the pubococcygeus, iliococcygeus, and puborectalis muscles. *int urogynecol. J Pelvic Floor Dysfunct.* 2007.
11. Sobotta. *Atlas de Anatomía Humana.* vol. 2. Putz - Pabst. 2006. Editorial Panamericana.
12. Baurant E., De Bisschop E., Vaini-elies V., Massonnat J., Aleman I., Buntinx J., et al. La prise en charge moderne des névralgies pudendales. A partir d'une série de 212 patientes et 104 interventions de décompression. *J Gynecol Obstet Biol Reprod (Paris).* 2003; 32:705-12.
13. Andersen K.V., Bovim G. Impotence and nerve entrapment in long distance amateur cyclists. *Acta Neurol Scand.* 1997; 95:233-40.
14. Kiff E.S., Barnes P.R., Swash M. Evidence of pudendal neuropathy in patients with perineal descent and chronic straining at stool. *Gut.* 1984; 25:1279-82.
15. Shafik A. Pudendal canal decompression for the treatment of fecal incontinence in complete rectal prolapse. *Am Surg.* 1996; 62:339-43.
16. Shafik A. Pudendal canal syndrome as a cause of vulvodynia and its treatment by pudendal nerve decompression. *Eur J Obstet Gynecol Reprod.* 1998; 80:215-20.
17. Benson J.T., McClellan E. The effect of vaginal dissection on the pudendal nerve. *Obstet Gynecol.* 1993; 82:387-9.
18. Antolak S.J.J., Hough D.M., Pawlina W., Spinner R.J. Anatomical basis of chronic pelvic pain syndrome: the ischial spine and pudendal nerve entrapment. *Med Hypotheses.* 2002; 59:349-53.
19. Pisani R., Stubinski R., Datti R. Entrapment neuropathy of the internal pudendal nerve. Report of two cases. *Scand J Urol Nephrol.* 1997; 31:407-10.
20. Pessis E., Drapé J.L., Guérini H., Bach F., Feydy A., Chevrot A. Nerve and vascular entrapment in athletes. *J Radiol.* 2007; 88(1 pt 2):156-71.
21. Lien K.C., Morgan D.M., Delancey J.O., Ashton-Miller J.A. Pudendal nerve stretch during vaginal birth: a 3-d computer simulation. *Am J Obstet Gynecol.* 2005; 192:1669-76.
22. Soga H., Nagata I., Murakami G., Yajima T., Takenaka A., Fujisawa M., et al. A histotopographic study of the perineal body in elderly women: the surgical applicability of novel histological findings. *Int Urogynecol J Pelvic Floor Dysfunct.* 2007.
23. Sunderland S. *Nerves and Injuries.* Ed. Churchill Livingstone; 1976.
24. Butler D.S. *Movilización del sistema nervioso.* Ed. Paidotribo; 2002.
25. Shafik A. Pudendal canal syndrome. A new etiological factor in prostatodynia and its treatment by pudendal canal decompression. *Pain Digest.* 1998; 8:32-6.
26. Shafik A. Pudendal canal decompression in the treatment of erectile dysfunction. *Arch Androl.* 1994; 32:141-9.
27. Loeser J. *Terapeutica del dolor.* Bonica. vol. II. Ed. McGraw-Hill; 2003. p. 1858.
28. Beco J., Klimov D., Bex M. Pudendal nerve decompression in perineology: a case series. *Bmc Surg.* 2004; 30:15.
29. Mollo M., Baurant E., Rossi-Seignert A.-K., Collet S., Boyer R., Thiers-Baurant D. Evaluation of diagnostic accuracy of colour duplex scanning, compared to electromyography, diagnostic score and surgical outcomes, in pudendal neuralgia by entrapment: a prospective study on 96 patients. *Pain.* 2009; 142:159-63.
30. Bisschop E, Baurant E. EMG: which one and why? Considerations regarding pudendal nerve

-
- terminal motor latencies (pntml). 31 Meeting Annual of the International Urogynecological Association (IUGA 2006). Encontrado en internet: www.perineology.com/files/de-bisschop-athens2006.pdf
31. Kiff E., Swash M. Slowed conduction in the pudendal nerves in idiopathic (neurogenic) faecal incontinence. *Br J Surg.* 1984; 71:614-6
32. González-Hidalgo M. Exploración neurofisiológica del suelo de la pelvis. *Rev Neurol.* 1998; 26:432-8.
33. Wallace J.M. Update on pharmacotherapy guidelines for treatment of neuropathic pain. *Curr Pain Headache Rep.* 2007; 11:208-14.
34. Harkins S., Linford J., Cohen J., Kramer T., Cueva L. Administration of clonazepam in the treatment of tmd and associated myofascial pain: a double-blind pilot study. *J Craniomandib Disord.* 1991; 5:179-86.
35. Sator-katzenschlager S.M., Scharbert G., Kress H.G., Frickey N., Ellend A., Gleiss A., et al. Chronic pelvic pain treated with gabapentin and amitriptyline: a randomized controlled pilot study. *Wien klin wochenschr.* 2005; 117:761-8.
36. Kovacs P., Gruber H., Piegger J., Bodner G. New, simple, ultrasound-guided infiltration of the pudendal nerve: ultrasonographic technique. *Dis Colon Rectum.* 2001; 44:1381-5.
37. Anderson R.U., Wise D., Sawyer T., Chan Ca. Sexual dysfunction in men with chronic prostatitis/chronic pelvic pain syndrome: improvement after trigger point release and paradoxical relaxation training. *J Urol.* 2006; 176(4 pt 1):. 1534-8; discussion 1538-9.
38. Hsieh Y.L., Kao M.J., Kuan T.S., Chen S.M., Chen J.T., Hong C.Z. Dry needling to a key myofascial trigger point may reduce the irritability of satellite mtrps. *Am J Phys Med Rehabil.* 2007; 86:397-403.
39. Popeney C., Ansell V., Renney K. Pudendal entrapment as an etiology of chronic perineal pain: diagnosis and treatment. *Neurourol Urodyn.* 2007.
40. Shafik A. Pudendal canal syndrome: description of a new syndrome and its treatment. Report of seven cases. *Coloproctology.* 1991; 13:102-9.
41. Robert R., Labat J.J., Bensignor M., Glemain P., Deschamps C., Raoul S., et al. Decompression and transposition of the pudendal nerve in pudendal neuralgia: a randomized controlled trial and long-term evaluation. *Eur Urol.* 2005; 47:403-8.
42. Mouchel J, Mouchel T, Zaka P. Trans-perineal pudendal nerve decompression. 31 Meeting Annual of the International Urogynecological Association (IUGA 2006). Disponible en: www.perineology.com/files/mouchel-athens2006.pdf
43. Weiss J. Treatment options for persistent pain following pudendal nerve decompression surgery. 31 Meeting annual of the international urogynecological association (iuga 2006). Disponible en: www.perineology.com/files/weiss-athens2006.pdf
-